

Locomotion and Movement

Multiple Choice Questions (MCQs)

Q. 1 Match the following columns.

Column I	Column II
A. Fast muscle fibres	1. Myoglobin
B. Slow muscle fibres	2. Lactic acid
C. Actin filament	3. Contractile unit
D. Sarcomere	4. I-band

Codes

A	B	C	D	A	B	C	D
(a) 1	2	4	3	(b) 2	1	3	4
(c) 2	1	4	3	(d) 3	2	4	1

- Ans. (c) 1. **Fast muscle fibres** contract spontaneously and reach anaerobic conditions in shorter time, so as to accumulate lactic acid faster in the muscles.
2. **Slow muscle fibres** have better ability to endure, as they are resistant to fatigue and contract slowly, it is because, of accumulation, of large amount, of myoglobin in them.
3. **Actin filament** form the isometric band in the muscle fibre because it is the only this actin protein which is present in that region.
4. **Sarcomere** is the contractile unit of skeletal muscle.

Q. 2 Ribs are attached to

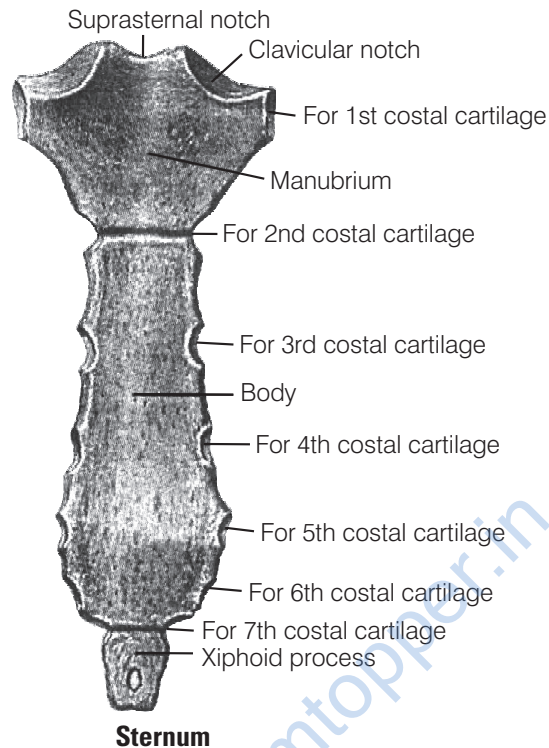
- (a) scapula (b) sternum (c) clavicle (d) ilium

💡 **Thinking Process**

There are 12 pair of ribs which forms the bony lateral walls of the thoracic cage.

- Ans. (b) **Sternum** This is a flat bone present just beneath the skin in the middle of the chest. It is about 15 cm long. It consist of three parts, i.e., **manubrium** the upper most part, **body** the middle portion and **xiphoid process** is the tip of the bone.

The true ribs (7 pairs) are attached to the **sternum**. While the, **scapula** and clavicle together constitute to form pectoral girdle, and **ilium** is a part of **pelvic girdle**.



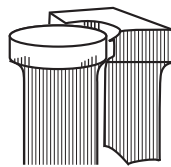
Q. 3 What is the type of movable joint present between the atlas and axis?

- (a) Pivot (b) Saddle (c) Hinge (d) Gliding

Thinking Process

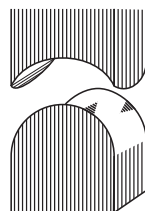
The structural arrangement of tissues by which bones are joined together are called joints.

Ans. (a) Pivot joint is the joints found between the atlas and axis and between the radius and ulna just below the elbow .This joint allows the movement in only one plane. In a pivot joint, rounded or pointed bone fits into a shallow depression of another bone.



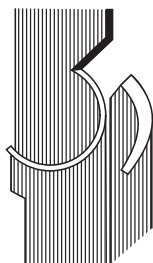
Pivot joint

Whereas, **saddle joint** provides free movement in two planes back-forth and side to side. The projection of one bone fits in saddle-shaped depression of another bone. The joint between the carpal and metacarpel of thumb in the hand is an example of saddle joint.



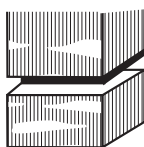
Saddle joint

Hinge joint allows movement primarily in one plane. In a hinge joint reel (spoon) like surface of one bone fits into the concave surface of another bone for example the elbow, the knee, ankle etc.



Hinge joint

Gliding joint also known as plane joint, it is a common type of synovial joint formed between bones that meet at flat or nearly flat articulating surface examples of gliding joint include carpal bones of the wrist and joint between the carpal and metacarpal of the palm.

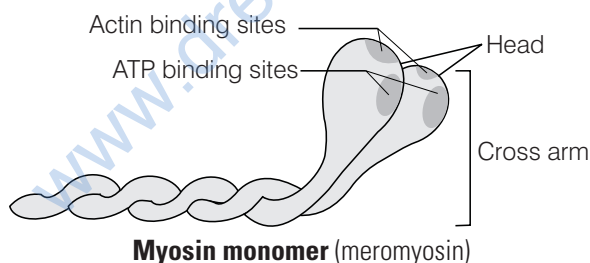


Gliding joint

Q. 4 ATPase of the muscle is located in

- (a) actinin (b) troponin (c) myosin (d) actin

Ans. (c) The globular head of **myosin** in muscle is an active ATPase enzyme having binding sites for ATP and active site for actin.



While the ATPase is not found in actinin, troponin or actin of muscle fibre.

Q. 5 Intervertebral disc is found in the vertebral column of

- (a) birds (b) reptiles (c) mammals (d) amphibians

Ans. (c) **Intervertebral disc** is found in the vertebral column of **mammals**. These are present between the bodies of adjacent vertebrae from second cervical vertebra to the sacrum. Each disc consist of an outer fibrous ring made of fibrocartilage and an inner soft pulpy, highly elastic substance.

This disc are majorly involved in formation of strong joints that permits various movements of the **vertebral column** and absorb **vertical shockes**.

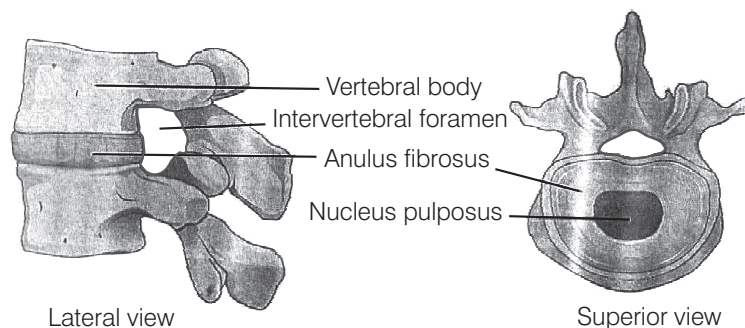


Diagram depicting intervertebral disc

Intervertebral disc is not found in the vertebral column of birds reptiles or ambhians.

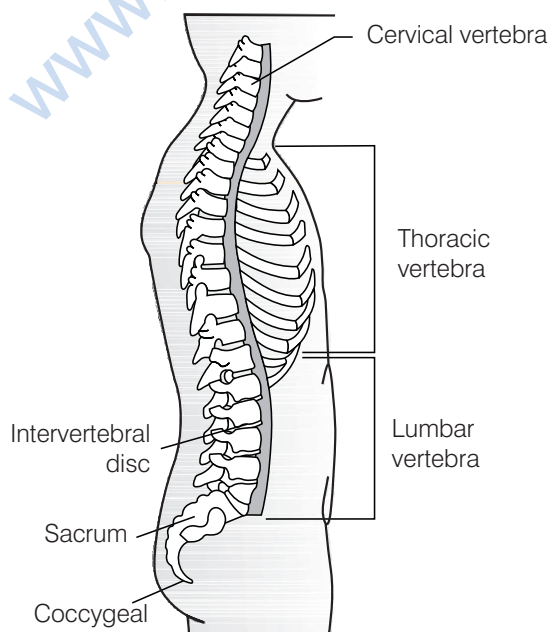
Q. 6 Which one of the following is showing the correct sequential order of vertebrae in the vertebral column of human beings?

- (a) Cervical — lumbar — thoracic — sacral — coccygeal
- (b) Cervical — thoracic — sacral — lumbar — coccygeal
- (c) Cervical — sacral — thoracic — lumbar — coccygeal
- (d) Cervical — thoracic — lumbar — sacral — coccygeal

💡 Thinking Process

Our vertebral column is formed by 26 serially arranged units called vertebrae, there are dorsally placed, extending from the base of the skull and constitutes the main frame work of the trunk.

Ans. (d) The correct sequence showing the vertebral column of human being is Cervical — thoracic — lumbar — sacral — coccygeal



Vertebral column (right lateral view)

Whereas, the other sequential order of vertebrae are wrong.

Q. 7 Which one of the following pair is incorrect?

- (a) Hinge joint – between humerus and pectoral girdle
- (b) Pivot joint – between atlas, axis and occipital condyle
- (c) Gliding joint – between the carpals
- (d) Saddle joint – between carpal and metacarpals of thumb

💡 Thinking Process

Joints are points of contact between two bones or between bones and cartilages.

Ans. (a) The joint present between humerus and pectoral girdle is ball and socket joint. Hinge joint is present between atlas and axis not between humerus and pectoral girdle. The elbow, knee, ankle and interphalangeal joints are the examples of hinge joints.

(Also, refer to Q. 3)

Rest of the pair are correct regarding to the presence of joints.

Q. 8 Knee joint and elbow joints are examples of

- (a) saddle joint
- (b) ball and socket joint
- (c) pivot joint
- (d) hinge joint

Ans. (d) Knee joint and elbow joints are examples of **hinge joints**.

(Also, refer to Q. 3 and 7)

Q. 9 Macrophages and leucocytes exhibit

- (a) ciliary movement
- (b) flagellar movement
- (c) amoeboid movement
- (d) gliding movement

💡 Thinking Process

In some cells microfilaments are involved in showcasing amoeboid movement.

Ans. (c) Some specialised cells in blood like macrophages and leucocytes exhibit amoeboid movement. They have the ability to reach the interstitial fluid by squeezing through the thin walls of blood vessels, while ciliary movement flagellar movement or gliding movement are not shown by macrophages and leucocytes.

Q. 10 Which one of the following is not a disorder of bone?

- (a) Arthritis
- (b) Osteoporosis
- (c) Rickets
- (d) Atherosclerosis

Ans. (d) Atherosclerosis also known as **arteriosclerotic vascular disease**, where arteries wall get thickens as a result of invasion and accumulation of WBC, containing both living active WBCs (white blood cells) and remnants of dead WBC's along with **cholesterol** and **triglycerides**. Remaining diseases, i.e., arthritis, osteoporosis and rickets are bone disorders.

Q. 11 Which one of the following statement is incorrect?

- (a) Heart muscles are striated and involuntary
- (b) The muscles of hands and legs are striated and voluntary
- (c) The muscles located in the inner walls of alimentary canal are striated and involuntary
- (d) Muscles located in the reproductive tracts are unstriated and involuntary

💡 Thinking Process

*The walls of internal organs such as the **blood vessels, stomach and intestine** contain **smooth muscles**.*

Ans. (c) Smooth muscles are 'involuntary' and **non-striated muscles** as they cannot be controlled directly like that of skeletal muscles which are voluntary, controlled and possess striations. They, inner walls of alimentary canal are non-striated and involuntary muscles. Rest other statements are correct.

Q. 12 Which one of the following statements is true?

- (a) Head of humerus bone articulates with acetabulum of pectoral girdle.
- (b) Head of humerus bone articulates with glenoid cavity of pectoral girdle.
- (c) Head of humerus bone articulates with a cavity called acetabulum of pelvic girdle.
- (d) Head of humerus bone articulates with a glenoid cavity of pelvic girdle.

💡 Thinking Process

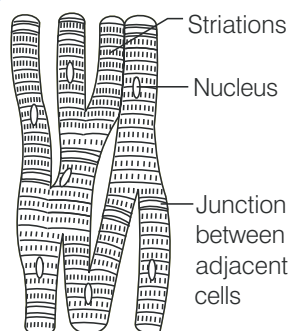
Skull, vertebral column, ribs and sternum constitute the axial skeleton. Limb, bones and girdles form the appendicular skeleton.

Ans. (b) Head of humerus bone articulates with the glenoid cavity of pectoral girdle. This articulation results in the formation of ball and socket joints, e.g., ball and socket joints present in shoulder while other statement are incorrect.

Q. 13 Muscles with characteristic striations and involuntary are

- (a) muscles in the wall of alimentary canal
- (b) muscles of the heart
- (c) muscles assisting locomotion
- (d) muscles of the eyelids

Ans. (b) Cardiac muscle fibres are supplied with both **central** and **autonomic nervous system** and are not under the control of the will of the **animal**, i.e., they are involuntary. These muscles possess striation but they never get fatigued as the myofibrils of heart have transverse faint dark and light bands which alternate with each other giving them striped appearance.



Structure of cardiac muscle

While muscles of the wall of alimentary canal are smooth muscle, i.e., non-striated and involuntary, muscle assisting locomotion, i.e., skeletal muscles are striated and voluntary and muscles of eyelid are involuntary but striations muscles this the other options are wrong.

Q. 14 Match the following columns.

Column I	Column II
A. Sternum	1. Synovial fluid
B. Glenoid cavity	2. Vertebrae
C. Freely movable joint	3. Pectoral girdle
D. Cartilagenous joint	4. Flat bones

Codes

A	B	C	D	A	B	C	D
(a) 2	1	3	4	(b) 4	3	1	2
(c) 2	1	4	3	(d) 4	1	2	4

Ans. (b) A. → (4) B. → (3) C. → (1) D. → (2).

Sternum is a flat bone present just under beneath the skin in the middle of the front of the chest.

Glenoid Cavity is the depression which articulates with the head of the humerus to form the ball and socket joint in pectoral girdle.

Freely Movable Joints are characterised by the presence of a fluid filled synovial cavity between the articulating surface of the two bones. This fluids represents the **synovial fluid**, e.g., in gliding and hinge joints.

Cartilagenous Joints are present between the adjacent vertebrae in the vertebral column.

Very Short Answer Type Questions

Q. 1 Name the cells/tissues in human body which

- (a) exhibit amoeboid movement (b) exhibit ciliary movement

💡 Thinking Process

Cells of the human body exhibit three main types of movements, namely amoeboid, ciliary and muscular.

Ans. (a) Macrophages and leucocytes in blood exhibit **amoeboid movement**. Cytoskeletal elements like microfilaments are also involved in amoeboid movement.

(b) **Ciliary Movement** These types of movements occurs mostly in the internal organs, which are lined by the **ciliated epithelium**. e.g., cilia in trachea helps in removing dust particle and foreign substances inhaled along with atmospheric air.

Passage of ova through the female reproductive tract is also facilitated by the **ciliary movement**. This is due to the presence of ciliated epithelium in the Fallopian tube.

Q. 2 Locomotion requires a perfect coordinated activity of muscular systems.

Ans. Locomotion requires a perfect coordinated activity of muscular, skeletal and neural systems.

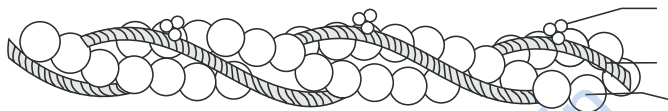
Q. 3 Sarcolemma, sarcoplasm and sarcoplasmic reticulum refer to particular type of cell in our body. Which is this cell and to what parts of that cell do these names refer to?

💡 Thinking Process

Mechanism of contraction in our body occurs through skeletal muscles made of a number of muscle bundles. Each muscle bundle contains a number of muscle fibres.

Ans. These parts belong to the **muscle fibre**, which is lined by the plasma membrane called sarcolemma. Muscle fibre is a syncytium because **sarcoplasm** (the cytoplasm) of muscle fibre contains number of nuclei and **sarcoplasmic reticulum** is the endoplasmic reticulum of the muscle fibre and is the store house of calcium ions.

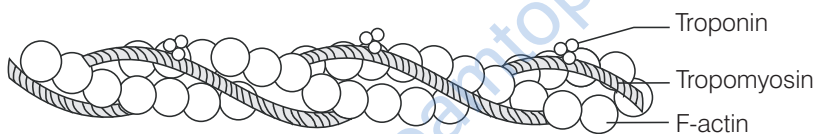
Q. 4 Label the different components of actin filament in the diagram given below



💡 Thinking Process

Each actin filament is made of two 'F' (filamentous) actins helically wound to each other and each 'F' actin is a polymer of monomeric 'G' (globular) actins..

Ans. Representing different component of actin filament



Q. 5 The three tiny bones present in middle ear are called ear ossicles. Write them in correct sequence beginning from ear drum.

Ans. Each middle ear contains three tiny bones, named, i.e., malleus, incus and stapes which are collectively called as **ear ossicles**.

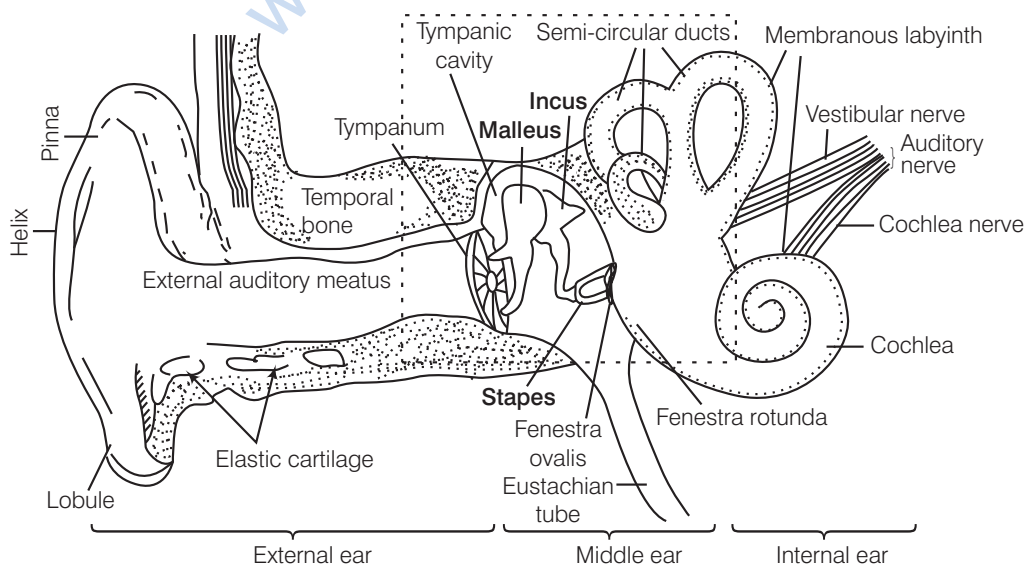
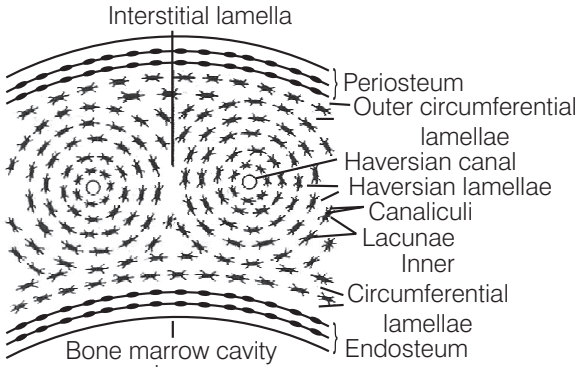
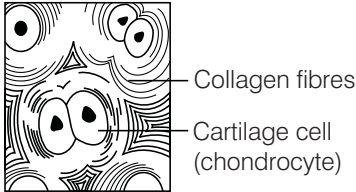


Diagram demonstrating parts of human ear and the three tiny bones in the middle ear

Q. 6 What is the difference between the matrix of bones and cartilage?

Ans. *Difference between the matrix of bones and cartilage*

Matrix of Bones	Matrix of Cartilage
Matrix of bones has an inflexible material, the ossein .	Matrix of cartilage has a flexible material, the chondrin .
Matrix of bones contains calcium salts .	Calcium salts may or may not be present in matrix.
	

Q. 7 Which tissue is afflicted by myasthenia gravis? What is the underlying cause.

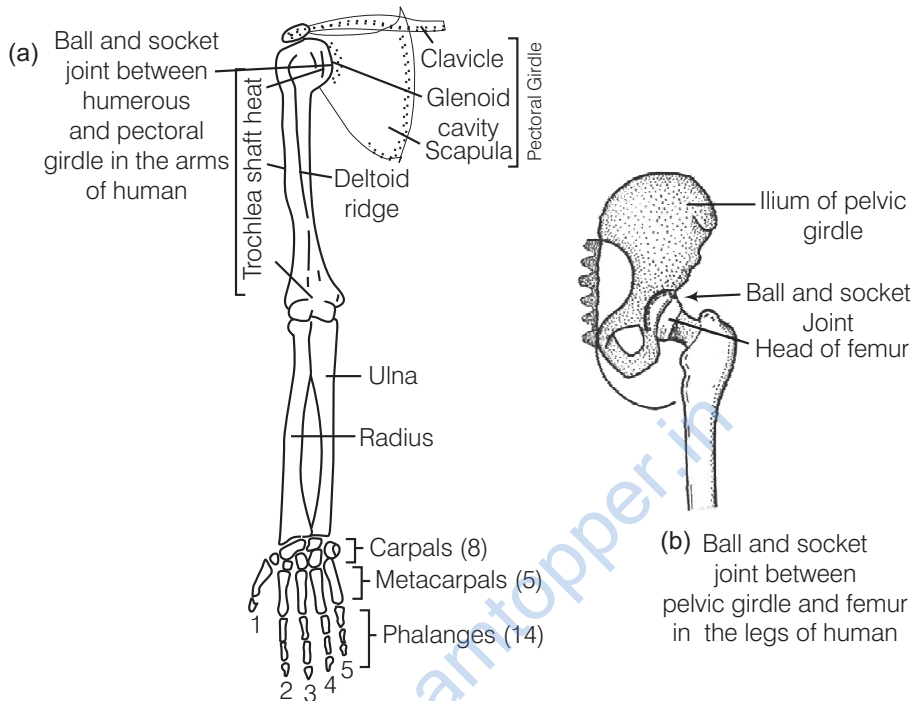
Ans. **Myasthenia gravis** is an autoimmune disorder of skeletal muscle, affecting neuromuscular junction, that leads to fatigue, weakening and paralysis of the **skeletal muscle**.

Q. 8 How do our bone joints function without grinding noise and pain?

Ans. The presence of **synovial fluid**, between articulating surface of the two bones enclosed within synovial cavity of synovial joints to makes our joints to function without grinding noise and pain.

Q. 9 Give the location of a ball and socket joint in a human body

Ans. **Ball and socket joint** are present between **humerus** and **pectoral girdle**. These joints allows free movement of bone in all direction. e.g., shoulder joints (humerus bone in socket of pectoral girdle) and hip joints (femur bone in socket of pelvic girdle).



Ball and socket joint

Q. 10 Our forearm is made of three different bones. Comment.

Ans. Our forearm is made of three different bones, i.e., humerus, radius and ulna. These bones can be seen in following figure

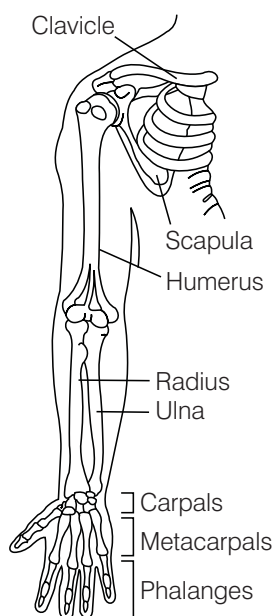


Diagram illustrating forearm bones

Short Answer Type Questions

Q. 1 With respect to rib cage, explain the following

- (a) bicephalic ribs
- (b) true ribs
- (c) floating ribs

Thinking Process

There are 12 pairs of ribs. Each rib consist of a thin flat bone connected dorsally to the vertebral column and ventrally to the sternum.

Ans. (a) **Bicephalic ribs**, each ribs has two articulating surfaces on its dorsal end hence, are called as **bicephalic ribs**.

(b) **True ribs** are the first seven pairs of ribs Dorsally these ribs are attached to the thoracic vertebrae and ventrally connected to the sternum with the help of **hyaline cartilage**.

(c) **Floating ribs** are the last two pair (11th and 12th) of ribs and are not connected ventrally to the sternum therefore, called as **floating ribs**.

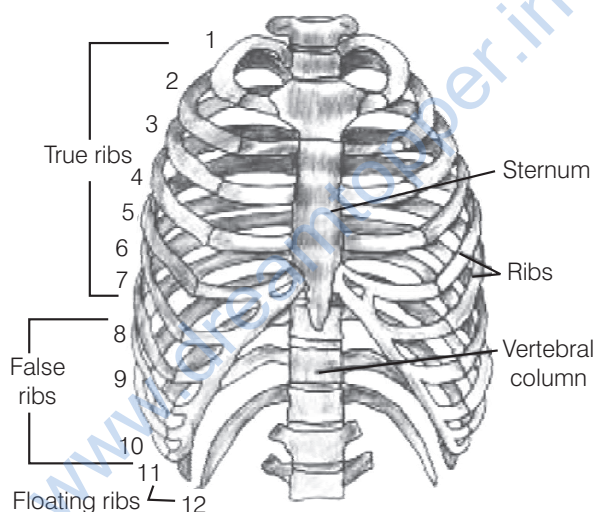


Diagram representing ribs and rib cage

Q. 2 In old age, people often suffer from stiff and inflamed joints. What is this condition called? What are the possible reasons for these symptoms?

Ans. The condition of stiff and inflamed joints is called as **osteoporosis**. It is an age-related disorder characterised by decreased bone mass and increased chances of fractures. Decreased levels of estrogen is a common cause for osteoporosis in females after menopause, in old aged females.

Q. 3 Exchange of calcium between bone and extracellular fluid takes place under the influence of certain hormones

- (a) What will happen if more of Ca^{2+} is in extracellular fluid?
- (b) What will happen if very less amount of Ca^{2+} is in the extracellular fluid?

Thinking Process

Parathyroid and thyroid glands, functions under the feed back control of blood calcium level.

Ans. (a) More Ca^{2+} concentration in extracellular fluid is associated with **hyperparathyroidism**. It causes **demineralisation**, resulting in **softening** and **bending** of the bones. This condition leads to **osteoporosis**.

(b) Very less amount of Ca^{2+} in extracellular fluid is associated with **hypoparathyroidism**. This increases the excitability of nerves and muscles, causing cramps, sustained contraction of the muscles of larynx, face, hands and feet. This disorder is called **parathyroidtetany** or **hypercalcemic tetany**.

Q. 4 Name atleast two hormones which result in fluctuation of Ca^{2+} level.

Ans. Parathyroid hormone and calcitonin results in the fluctuation of Ca^{2+} level. **Parathyroid Hormone** (PTH) increases the Ca^{2+} levels in the blood. PTH acts on the bones and stimulates the process of bone resorption (dissolution/demineralisation).

PTH also stimulates reabsorption of Ca^{2+} by the renal tubules and increases Ca^{2+} absorption from the digested food.

Calcitonin is a **32-amino acid linear polypeptide hormone**, that is produced in humans primarily by the parafollicular cells of the thyroid. It acts by reducing blood calcium (Ca^{2+}), levels opposing the effect of Parathyroid Hormone (PTH).

Q. 5 Rahul exercises regularly by visiting a gymnasium. Of late he is gaining weight. What could be the reason? Choose the correct answer and elaborate.

- (a) Rahul has gained weight due to accumulation of fats in body
- (b) Rahul has gained weight due to increased muscle and less of fat
- (c) Rahul has gained weight because his muscle shape has improved
- (d) Rahul has gained weight because he is accumulating water in the body

Ans. (b) Rahul has gained weight because his muscle shape has changed. Regular exercise increase the body muscle as there is an enlargement of muscles due to increase in the amount of sarcoplasm and mitochondria and the strength he developed led him gain the mass and size of body muscle and reduction in fat content.

Q. 6 Radha was running on a treadmill at a great speed for 15 minutes continuously. She stopped the treadmill and abruptly came out. For the next few minutes, she was breathing heavily/fast. Answer the following questions.

- (a) What happened to her muscles when she did strenuously exercised?
- (b) How did her breathing rate change?

Ans. (a) Due, to continuous exercise her muscles got fatigues because of the accumulation of lactic acid within skeletal muscles. Pain is also oftenly experienced in the fatigued muscles.

(b) Her breathing rate changes from normal to high as during exercise, her body muscle require more oxygen for the ATP production, than the normal value, hence her breathing enhances, to take most oxygen from the atmosphere.

Q. 7 Write a few lines about gout.

Ans. Gout is a disease, caused due to defect in **purine metabolism**. It causes accumulation of excess of uric acid and its crystals in the joints. The level of uric acid and crystals of its salts get raised in blood causing their accumulation in the joints causes **gouty arthritis**. The excess of urates in blood can also lead to the formation stones in the kidneys.

Q. 8 What is the source of energy for muscle contraction?

Ans. ATP (Adenosin Triphosphate) is the source of energy for muscle contraction. The head of each myosin molecule contains an enzyme called myosin ATPase.

In the presence of this enzyme along with Ca^{2+} then, and Mg^{2+} ions the ATP molecule breaks down into ADP and inorganic phosphate, thus releasing energy in the head of myosin.



Energy from ATP causes energised myosin to cross bridges and to bind with actin and in this way initiates muscle contraction.

Q. 9 What are the points for articulation of pelvic and pectoral girdles?**Thinking Process**

Pectoral and pelvic girdle bones help in the articulation of the upper and the lower limbs respectively with the axial skeleton.

Ans. Pectoral girdle Each half of the pectoral girdle consist of a clavicle and a scapula. The dorsal flat, triangular body of scapula has a slightly elevated ridge called the spine that, projects a flat expanded process called the acromion and the clavicle articulating with it.

Below the acromion their is a depression called the glenoid cavity which articulates with the head of the humerus to form the **shoulder joint**. **Pelvic girdle** consist of two coxal bones. each formed by the fusion of three bones, **ilium**, **ischium** and **pubis**. It articulates with femur through a cavity called **acetabulum** forming thigh joint.

Long Answer Type Questions**Q. 1** Calcium ion concentration in blood affects muscle contraction. Does it lead to tetany in certain cases? How will you correlate fluctuation in blood calcium with tetany?**Thinking Process**

*Concentration of **calcium ion** (Ca^{2+}) in body fluid mainly affects the muscle contraction, as the binding of contractile proteins **actin** and **myosin** depends on it.*

Ans. For the muscle fibre to contract, the binding site on thin filaments must be uncovered. This occurs when Ca^{2+} bind to another set of regulatory proteins, called troponin complex which control the position of tropomyosin on the thin filament.

The calcium binding rearranges the tropomyosin, troponin complex, exposing the myosin-binding sites on the thin filament. When Ca^{2+} is present in the cytosol, the thin and thick filament slide past each other resulting in muscle contraction.

Similarly, when the Ca^{2+} concentration falls, the binding sites get covered and contraction stops.

In case of **tetany** there occur low calcium levels in body fluid due to diminished function of **parathyroid gland**. This gland is mainly involved in the secretion of **parathyroid hormone** which is associated in regulating calcium levels in blood. Tetany results in periodic painful muscular spasm (wild contraction) and tremors.

Q. 2 An elderly women slipped in the bathroom and had severe pain in her lower back. After X-ray examination doctors told her it is due to a slipped disc. What does that mean? How does it affect our health?

Ans. Slipped disc is a medical condition in which spine is affected due to wear and tear in the outer fibrous ring (anulus fibrosus) of an **intervertebral disc**, allowing the soft, central portion to bulge out beyond the damaged outer rings.

These intervertebral disc are present between the bodies of adjacent vertebrae from the **second cervical vertebra** to the **sacrum**. This discs form strong joints that permit various movements of vertebral column and absorbs vertical shock.

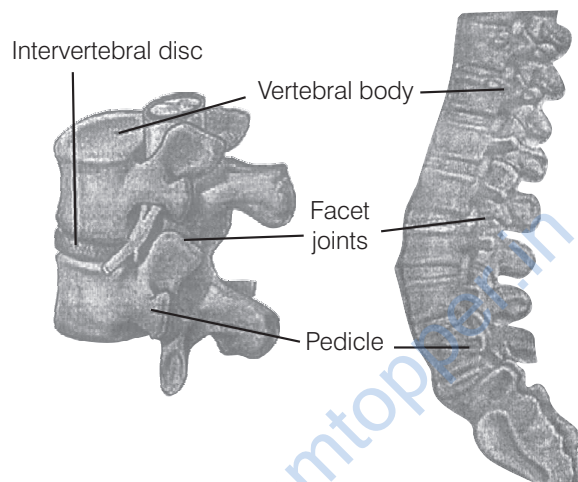


Diagram intervertebral disc

The cause of slip disc can be due to general wear and tear of intervertebral disc during performing various jobs, that require constant sitting and squatting. The slipped disc or herniation occurs in two regions of body, i.e., **cervical disc** and **lumber disc**.

Slip disc in lower back (lumber disc), lead to sharp pain in one part of leg due to sciatica, (disturbance in sciatic nerve), hip and cause numbness in other lower parts of the body.

Slip disc in neck region (cervical disc) leads to pain while moving neck near or over the shoulder bone or pain occurs while moving forearm, or fingers. It also causes numbness in shoulder, elbow, forearm and finger area.

Hence, slipped disc affect the upper and lower body parts, thus, influencing life style and health.

Q. 3 Explain sliding filament theory of muscle contraction with neat sketches.

💡 Thinking Process

The contraction of muscle fibre takes place by the sliding of the thin filaments over thick filaments.

Ans. Sliding filament theory

This theory is applicable to smooth, cardiac and skeletal muscles. *The essential features of this theory are as follows*

- (i) During muscle contraction, **thin myofilaments** slide inward towards the **H-zone**.
- (ii) The sarcomere, the basic unit of muscle contraction, shortens, without changing the length of thin and thick myofilaments.
- (iii) The cross-bridge of the thick myofilaments connect with the portions of actin of the thin myofilaments. These cross-bridge move on the surface of the thin myofilaments, resulting in the sliding of thin and thick myofilaments over each other.

- (iv) The length of the thick and thin myofilaments do not change during muscle contraction.
- (v) A muscle fibre maintains a resting potential under resting conditions just like a nerve fibre. As soon as a nerve impulse reaches the terminal end of the axon, small sacs called **synaptic vesicles** fuse with the axon membrane and release a chemical transmitter, called **acetylcholine**.

It diffuses across the **synaptic cleft** (the space between the axon membrane and the motor end plate) and binds to the receptor sites of the motor end plate.

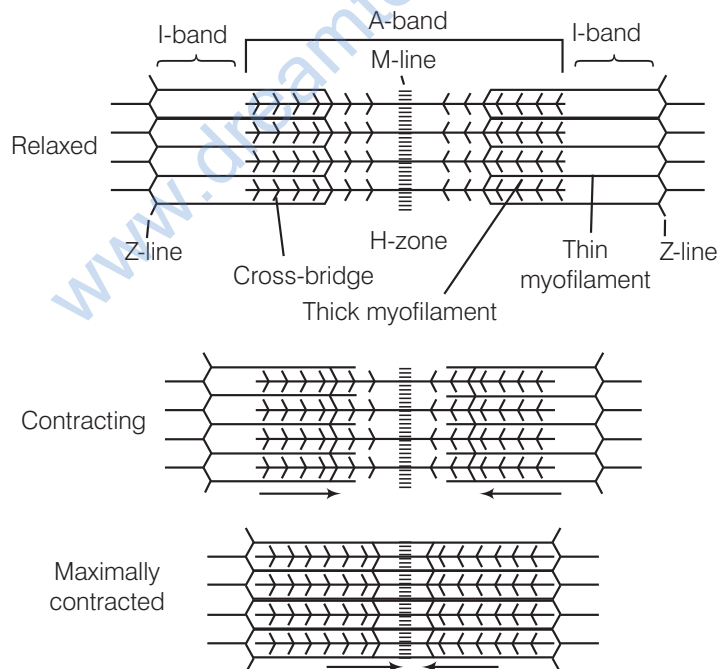
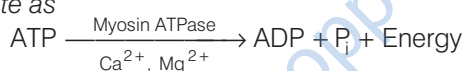
- (vi) As soon as depolarisation of the motor end plate reaches a certain level, it creates an **action potential**. After this, an enzyme **cholinesterase** present along with the receptor sites for acetylcholine breaks down acetylcholine into acetate and choline.

A portion of the choline diffuses back to the axon and is reused to synthesise more acetylcholine for the transmission of subsequent impulses.

- (vii) **Calcium** plays a key regulatory role in muscle contraction. The Ca^{2+} ions bind to troponin causing a change in its shape and position. This in turn alters the shape and position of tropomyosin.

This shift exposes the **active sites** on the **F-actin** molecules and myosin cross-bridges are then able to bind to these active sites.

- (viii) The head of each myosin molecule contains an enzyme **myosin ATPase**. In the presence of myosin ATPase, Ca^{2+} and Mg^{2+} ions, *ATP breaks down into ADP and inorganic phosphate as*



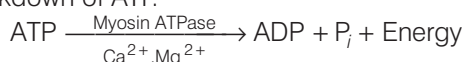
Sliding filament theory of muscle contraction

- (ix) Energy from ATP causes energised myosin cross-bridges to bind to actin. The energised cross-bridge move, causing the thin myofilaments to slide along the thick myofilaments. This movement is like the movement of the oars of a boat.
- (x) As stated earlier in theory, there is no shortening of thin and thick myofilaments. However, the sarcomere shortens, because of the sliding of the thin myofilaments produced by cross-bridge movements. The H-zone and I-band shorten, but the width of the A-band remains constant.

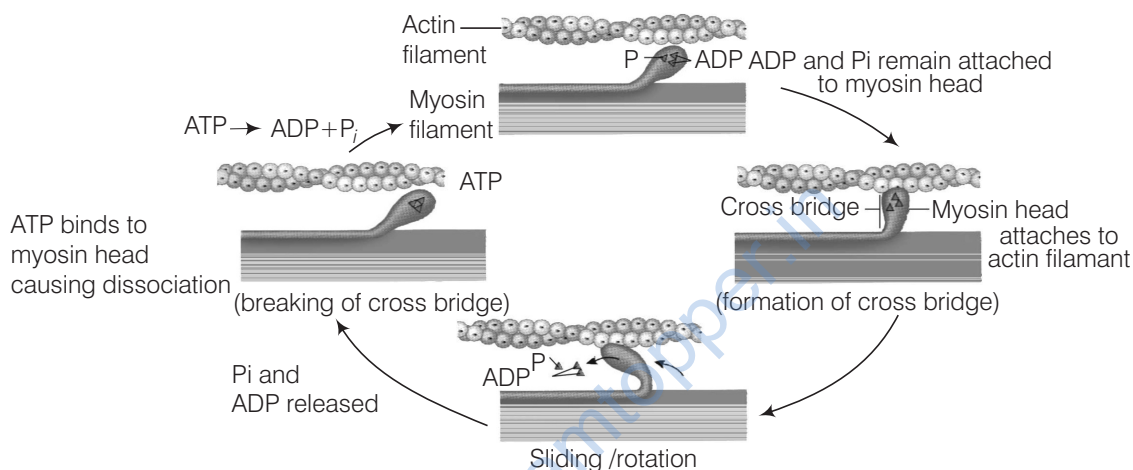
Q. 4 How does a muscle shorten during its contraction and return to its original form during relaxation?

Ans. Formation of cross-bridge between the actin and myosin filament help muscle to contract.

- (i) An ATP molecule joins the active site on myosin head of myosin myofilament. These heads contains an enzyme, **myosin ATPase** that along with Ca^{2+} and Mg^{2+} ions catalyses the breakdown of ATP.

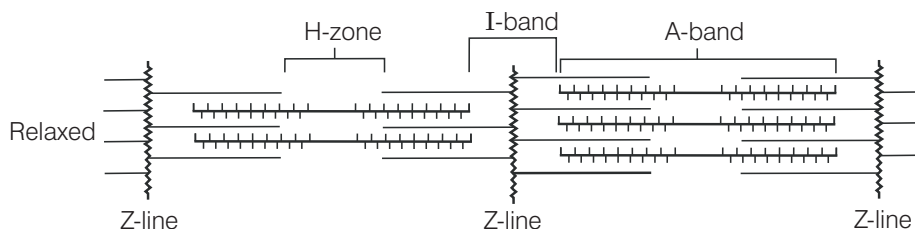


- (ii) The energy is transferred to myosin head which energises and straightens to join an active site on actin myofilament, forming a cross-bridge.



Stages in cross-bridge formation, rotation of head and breaking of cross-bridge

- (iii) The energised cross-bridges move, causing the attached actin filaments to move towards the centre of A-band. The Z-line is also pulled inwards causing shortening of sarcomere, *i.e.*, contraction. It is clear from the above explanation that during contraction A-bands retain the length, while I-bands get reduced.
- (iv) The myosin head releases ADP and P_i, relaxes to its low energy state. The head detaches from actin myofilaments when new ATP molecule joins it and cross-bridge are broken.
- (v) In repeating cycle, the free head cleaves the new ATP. The cycles of cross-bridge formation and breakage is repeated causing further sliding.



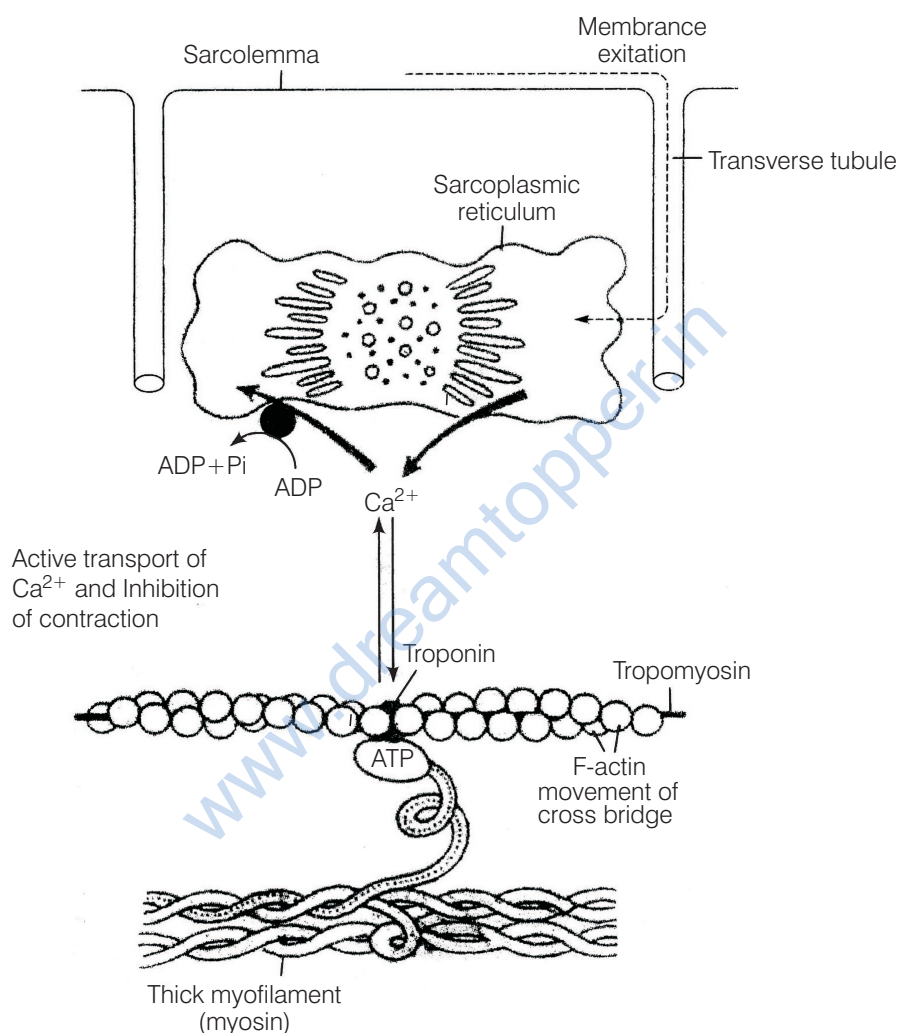
Showing movement of the thin filaments and the relative size of the I-band and H-zones

- (vi) Muscle relaxation occurs after contraction when the calcium ions are pumped back to the sarcoplasmic cisternae, thus, blocking the active sites on actin myofilaments. The Z-line returns to original position, *i.e.*, relaxation.

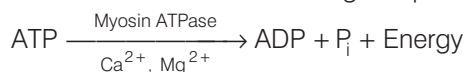
Q. 5 Discuss the role of Ca^{2+} ions in muscle contraction. Draw neat sketches to illustrate your answer.

Ans. Calcium plays a key regulatory role in muscle contraction. These ions bind to troponin causing change in its shape and position. This in turn alters the shape and position of tropomyosin. This shift exposes the active sites on the F-actin molecules and myosin cross-bridges able to bind to these **active sites**.

The complete process is outlined in the figure below



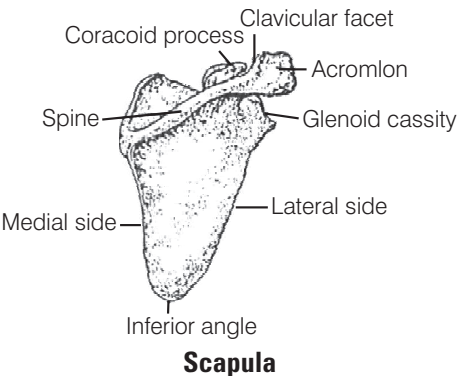
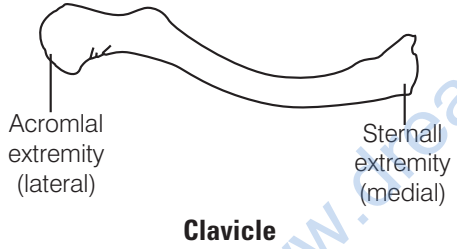
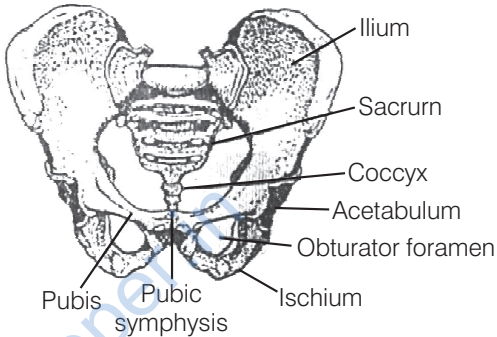
Role of calcium ion, is the contraction and relaxation process. The head of each myosin molecule contains an enzyme **myosin ATPase**. In the presence of myosin ATPase, Ca^{2+} and Mg^{2+} ions, ATP breaks down into ADP and inorganic phosphate as



Energy from ATP causes energised myosin cross-bridges to bind with actin.

Q. 6 Differentiate between pectoral and pelvic girdle.

Ans. The pectoral and pelvic girdle are responsible in providing support to the upper and lower body portions

Pectoral Girdle	Pelvic Girdle
<p>It occurs in the shoulder region, hence also called as shoulder girdle.</p> <p>Pectoral girdles are divided into two parts, i.e., one clavicle and one scapula.</p>  <p>Scapula</p>  <p>Clavicle</p> <p>Clavicle and scapula helps in articulation of the upper limb with axial skeleton.</p> <p>It has no articulation with the vertebral column.</p> <p>Bones associated with pectoral girdle are light, as they are not subjected to much stress.</p> <p>There perform like holding, lifting</p>	<p>It occurs in the hip region, hence also called as hip girdle.</p> <p>There is one pelvic girdle, which is formed by two, innominate bones. Each bone consist of three parts. i.e., ilium, ischium and pubis.</p>  <p>Human pelvis from anterior aspect</p> <p>The innominate at the middle of its lateral surface has a deep, cup shaped acetabulum. where head of the femur articulates the two halves of the pelvic girdle and meet ventrally to form public symphysis.</p> <p>It has articulation with vertebral column.</p> <p>Bones associated with pelvic girdle are hard as they are subjected to much stress</p> <p>There function like running, standing, jumping.</p>